

Histomorphological Study on The Prenatal Development of the Lenticular Papillae of One-Humped Camel (*Camelus Dromedarius*)

Bello A^{1*}, Alimi OA², Shehu SA¹ and Hena SA¹

¹Department of Veterinary Anatomy, Usmanu Danfodiyo University, Sokoto, Nigeria

²Department of Theriogenology and Animal production, Usmanu Danfodiyo University, Sokoto, Nigeria

*Corresponding Author: Bello A, Department of Veterinary Anatomy, Usmanu Danfodiyo University, Sokoto, Nigeria.

Received: February 21, 2017; Published: March 30, 2017

Abstract

Study involving an evaluation of fifteen [15] dromedarian camel fetuses was conducted to demonstrate the development of lenticular papillae using standard histomorphological methods. In the experiment, fifteen *Camelus dromedarius* foetuses obtained from Sokoto metropolitan abattoir at different gestational ages were used for the study. The weight, age, length, width and volume of fetuses, head and various segment of the tongue were observed. From the fifteen [15] samples used for the study, five [5] belongs to the first trimester, five [5] from the second trimester and five [5] belongs to the third trimester. A total of ten [10] foetuses were males and five [5] were females. Grossly, in all the stages of development, the tongues were observed to be elongated, with flat surfaces and rounded at the apices. At first trimester, the tongues were seen as smooth muscle mass, with almost uniform width and thickness throughout the length. They were uniformly pinkish, no pigmentation and no visual evidence of lingual papillae. At second trimester, the tongues were observed to have taken the normal shape of an adult tongue with variable size and shape of lingual papillae; tapering rostrally from the root to the apex. Biometrically, the weight of the foetuses were found to be 0.18 ± 0.05 to 21.70 ± 7.28 kg from the first trimester to third trimester, the crown - vertebral - rump - length were found to be 15.75 ± 4.42 to 94.00 ± 2.83 cm from the first trimester to the third trimester, weight of the head were found to be 25.05 ± 15.17 to 1120.00 ± 14.14 g and weight of the tongues were found to be 0.79 ± 0.22 to 116.25 ± 11.49 g from first trimester to third trimester of age. Histological observations showed that the lenticular papillae were generally lined with keratinised stratified (variable degree) squamous epithelium, which was composed by basal, spinosum, lucideum, granulosum and corneum layers. There was no evidence of seromucous glands in all the stages of development.

Keywords: Histomorphology; Camel; Lenticular; Papillae; Prenatal development

Volume 1 Issue 1 March 2017

© All Copy Rights are Reserved by Bello A., et al.

Introduction

The tongue in mammals possesses; three sections, root, body and tip; two surfaces as dorsal and ventral; two lateral margins which separate the dorsal and the ventral surfaces, meeting rostrally in the formation of the tip of the tongue. There are mechanic and gustatory papillae on the dorsal surface of the tongue (Bello., et al. 2013).

Citation: Bello A., et al. "Histomorphological Study on The Prenatal Development of the Lenticular Papillae of one-Humped Camel (*Camelus Dromedarius*)". *Multidisciplinary Advances in Veterinary Science* 1.1 (2017): 41-47.

The mechanic papillae (lenticular, filiform and conical) help chewing and swallowing foods while the gustatory papillae (circumvalate, fungi-form and foliate) receive the taste of foods (Peng, *et al.* 2008). The true camels (*Camelus dromedarius* and *Camelus bactrianus*) are among the largest mammalian species, adapted to the desert where thorny plants with rough and hard stems grow and with its high temperatures and extreme desiccation (Bello, *et al.* 2012).

The camel's mouth is very sturdy and is developed to maintain efficient feeding of these plants and is rubbery so that thorns and branches won't damage it (Bello, *et al.* 2013). Numerous research studies investigated morphogenesis of lingual papillae in various animal species (Ahpin, *et al.* 1989; Tichy, 1992; Fujimoto, *et al.* 1993; Iwasaki, *et al.* 1996a; Kulawik, 2005a, 2005b) and human (Witt & Reutter, 1997). Few reports are available on the morphological features of the camel papillae (Qayyum, *et al.* 1988; Erdunchoalu, *et al.* 2001; Peng, *et al.* 2008; Doughbag, 1988; Salehi, *et al.* 2010). The lenticular papillae on the outer line of papillae appeared to be numerous than those in the inner line. Nevertheless, the embryogenesis of the nature and/or morphologies of the lenticular papillae have not been previously investigated in this geographical location.

Most available reports on the morphological features of the camel tongue (Qayyum, *et al.* 1988; Erdunchoalu, *et al.* 2001; Peng, *et al.* 2008; Doughbag, 1988; Salehi, *et al.* 2010) were entirely concerned with structures of adult, thus there is paucity of information about the prenatal development of camel lenticular papillae in this area. In this research, gross changes, morphometric changes and histological differentiation involved in the development of the lenticular papillae in one-humped camel will be described. The study will also add to the existing information on the morphometric analysis in camels. Therefore this investigation was carried out to reveal and evaluate the pattern of the lenticular papillae differentiation during prenatal life in one humped camel (*Camelus dromedarius*).

Materials and Methods

The study was carried out on 15 fetuses of the one-humped camel collected from the metropolitan abattoir, Sokoto at different gestational ages. The collected fetuses were then taken to the Veterinary Anatomy laboratory of Usmanu Danfodiyo University; where the weight and age of the foetus were determined. The foetal body weight was measured using electrical (digital) weighing balance for the smaller fetuses and compression spring balance (AT-1422), size C-1, sensitivity of 20 kg X 50g in Kilogram for the bigger fetuses. The approximate age of the fetuses was estimated by using the following formula adopted by El-wishy, *et al.* 1981 and Bello, *et al.* 2012.

$$GA = (CVRL + 23.99)/0.366;$$

Where GA is age in days and CVRL is the Crown Vertebral Rump Length. Fetuses below 130 days were designated as first trimester, 131-260 days as second trimester and 261-390 days as third trimester [4]. Crown Vertebral Rump Length (CVRL) was measured (cm) as a curved line along the vertebral column from the point of the anterior fontanel or the frontal bone following the vertebral curvature to the base of the tail. Based on this, foetal samples were divided into 3 main groups as described by Bello, *et al.* 2013.

The fetuses were then placed on a dorsal recumbency and a caudo-lateral skin incision was made at the intermandibular fossa, ventral to the base of the pharynx. The organs were examined in situ and exteriorised. The length, weight, and width of each tongue were measured using ruler and thread, weighing balance, and vernier callipers, respectively. The length was taken from the cranial pole (tip) to the caudal pole (root) along the longitudinal axis while the width was taken as the distance between the two lateral aspects of the tongue, measured at the apex or the tip, mid-length (body) and root with vernier calliper, metric ruler for bigger tongues and recorded in millimeter. The Volume was determined by water displacement technique (Archimedes principle). The organs were weighed using an electronic weighing (Mettler® balance P1210, Mettler Instruments AG, Switzerland) with a sensitivity of 0.01 g. The data obtained were expressed as mean ± standard error of the mean (mean ± SEM).

1 cm² thick of sample from each segment was collected and fixed in 10% formalin solution. After fixation was achieved, the tissue sample was processed for paraffin blocks preparation. The sections of 5 µm were subjected to haematoxylin and eosin for routine

morphology (Luiz and Jose, 2005). The standard sections were examined under light microscope and micrographs taken using Sony digital camera (x5) with 12.1 mega pixel.

Result and Discussion

From the fifteen [15] samples used for the study, five [5] belongs to the first trimester, five [5] from the second trimester and five [5] belongs to the third trimester. A total of ten [10] fetuses were males and five [5] were females (Table: 1). The tongue of camel was developed as an elongated and dorsoventrally flattened organ along its cranial two-thirds on the floor of the buccal cavity between the rami of the mandible from first trimester to third trimester with a rounded apex and a well-developed torus (Figure: 1). This finding is in agreement with the previous studies of Qayyum, *et al.* (1988) on Llama; Erdunchaolu, *et al.* (2001) and Peng, *et al.* (2003) on Bacterian camel, Emura, *et al.* (2011a) on sheep; abundant as in ruminants Qayyum and Beg, (1991) and Prakash and Rao, (1996); Chamorro, *et al.* (1986) on Horse; Kumar, *et al.* (1998) and Tadjalli and Pazhoomand, (2004) on Sheep and in mouse, rat and hamster by Kurtul and Atalgin, (1998) and Iwasaki, *et al.*(2004).

Trimester	Mean CVRL (cm ± SEM)	Sex		Mean Weight (kg ± SEM)
		Male	Female	
1 st	15.75 ± 4.42	3	2	0.18 ± 0.05
2 nd	44.75 ± 10.78	3	2	2.37 ± 1.43
3 rd	94.00 ± 2.83	4	1	21.70 ± 7.28
Total		10	5	

Table 1: The mean CVRL, sex and mean weight of the fetuses at various gestational ages.

Grossly, in all the stages of development, the tongues were observed to be elongated, with flat surfaces and rounded at the apices (Plates I and II). At first trimester, the tongues were seen as smooth muscle mass, with almost uniform width and thickness throughout the length (Plates I). They were uniformly pinkish, no pigmentation and no visual evidence of lingual papillae (Plates I). At second trimester, the tongues were observed to have taken the normal shape of an adult tongue; tapering rostrally from the root to the tip or apex. The tongues were pinkish with prominent lingual papillae as evident at the posterior one-third of dorsal part of the tongue and less evident at the remaining two-thirds (Plates II). At third trimester, the tongues had developed into the typical adult tongue, with prominent lingual papillae at the tip, laterals, dorsum and the root. The tongue is relatively darkish as compared to those of first and second trimesters.

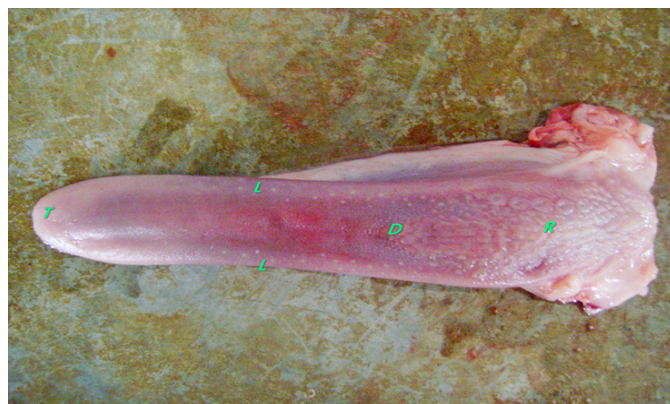

Plate I: Tongue of fetus at third trimester with clearly evident and differentiated lingual papillae X 75. at various gestational ages.

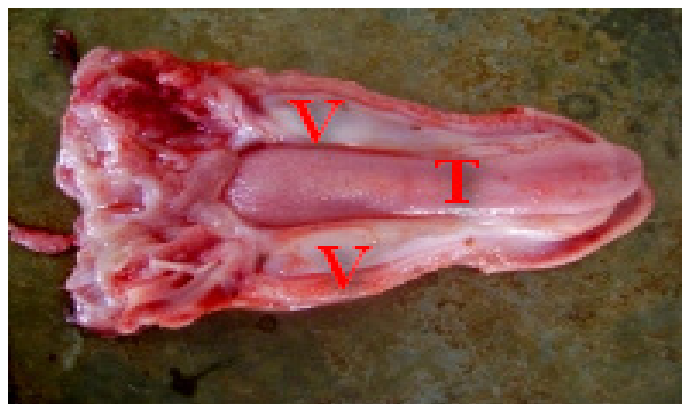


Plate II: Tongue Photograph showing camel fetus tongue at second trimester with clearly evident and differentiated lingual papillae X 75.

Biometrically, the weight of the fetuses were found to be 0.18 ± 0.05 to 21.70 ± 7.28 kg from the first trimester to third trimester, the crown-vertebral-rump-length were found to be 15.75 ± 4.42 to 94.00 ± 2.83 cm from the first trimester to the third trimester, weight of the head were found to be 25.05 ± 15.17 to 1120.00 ± 14.14 g and weight of the tongues were found to be 0.79 ± 0.22 to 116.25 ± 11.49 g from first trimester to third trimester (Table 2). The observed biometric study of the fetuses and the tongues were found to be progressively increasing with advancement in gestational ages. The weight of the foetus, head and tongue were found to increase significantly with advancement in gestational ages. This is in accordance with the work of Sonfada, *et al.* 2008 and Bello, *et al.* 2012 who observed that there was an increase in body weight across the trimesters in the foetus with advancement in pregnancy and that of Anderson, *et al.* (1987) that there was obvious body weight changes on MDX mice which seemed to increase with age.

Trimester	First	Second	Third
Length (cm \pm SEM)	2.05 ± 0.67	8.65 ± 1.66	14.9 ± 0.42
Width (mm \pm SEM)			
Tip	1.3 ± 0.20	9.50 ± 4.60	18.50 ± 3.20
Body	3.00 ± 1.40	12.30 ± 3.40	25.00 ± 0.70
Root	4.30 ± 2.30	14.50 ± 3.90	31.50 ± 1.10
Thickness (mm \pm SEM)			
Tip	0.07 ± 0.01	4.29 ± 0.53	5.50 ± 0.15
Body	0.28 ± 0.16	5.87 ± 1.43	10.78 ± 0.37
Root	1.56 ± 1.04	9.16 ± 2.90	16.35 ± 0.63

Table 2: The morphometrical parameters of the tongue at the various gestational ages.

From the observed length and width, the increment was in accordance with Bello, *et al.* (2012a) who showed that there was increase in the length of the digestive tract of camel with increase in gestational ages. This is also in line with Franco, *et al.* (1993); Bal and Ghoshal (1972) and Georgieva and Gerov (1975) on their works on digestive tract of bovine, porcine and caprine species respectively.

Histological observations of the study shown that, the tongue has three layers: tunica mucosa, tunica submucosa and tunica muscularis. The three layers were seen right from the first trimester, as shown in the Figure 1,2,3,4 and 5. The development of lingual papillae was found to be in succession; from the stages of ordinary epithelial cell linings with undifferentiated protrusions (papillae) and developing slightly into differentiated papillae, then finally to the developed papillae, with continuous maturity at post-natal stage (Figure: 4). These were seen with advancement in gestational age from first trimester through second trimester and to third trimester of age.

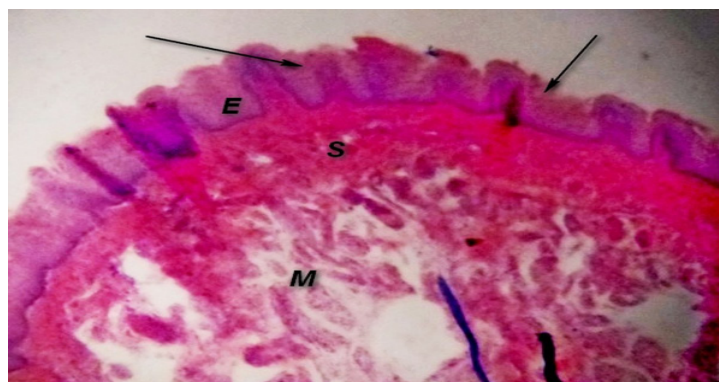


Figure 1: The Photomicrograph of camel tongue (TIP) at first trimester showing Tunica mucosa (E), Tunica submucosa (S) and Tunica muscularis (M) with slight differentiation of the epithelia cells in the formation of papillae (black arrow) H & E x200.

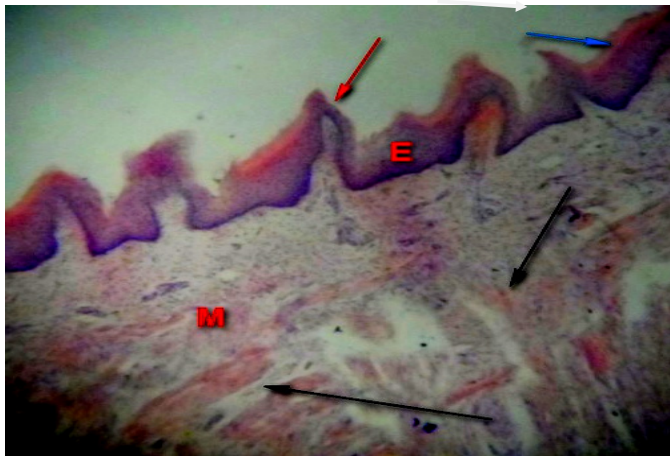


Figure 2: The Photomicrograph of camel tongue (TIP) at first trimester showing Tunica mucosa (E), Tunica submucosa (S) and Tunica muscularis (M) with slight differentiation of the epithelia cells in the formation of papillae (black arrow) H & E x200.

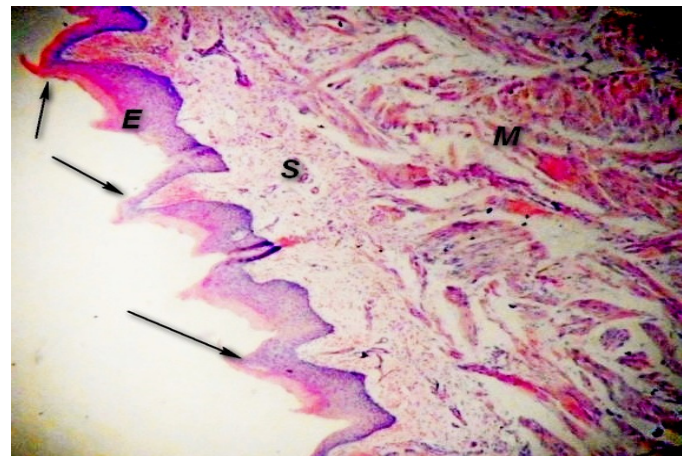


Figure 3: Photomicrograph of camel tongue (LATERAL) at third trimester showing Tunica mucosa (E), Tunica submucosa (S) and Tunica muscularis (M) with differentiation of the epithelia cells in the formation of lenticular papillae; (black arrow), H & E x200.

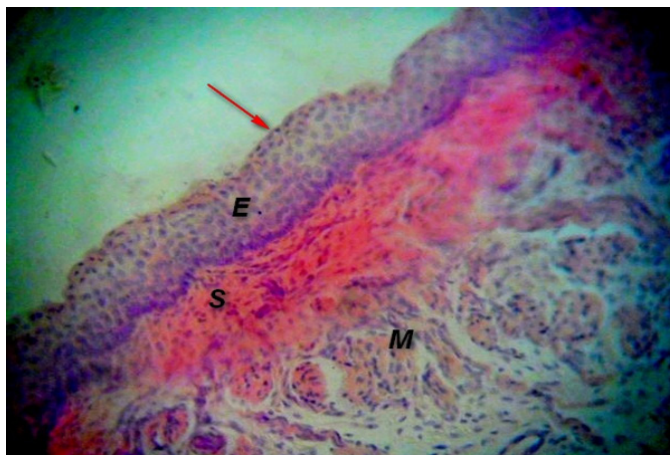


Figure 4: Photomicrograph of camel tongue (TIP) at first trimester showing Tunica mucosa (E), Tunica submucosa (S) and Tunica muscularis (M) with developed non-keratinized stratified squamous epithelium (red arrow) and developing undifferentiated skeletal muscle (M) H & E x300.

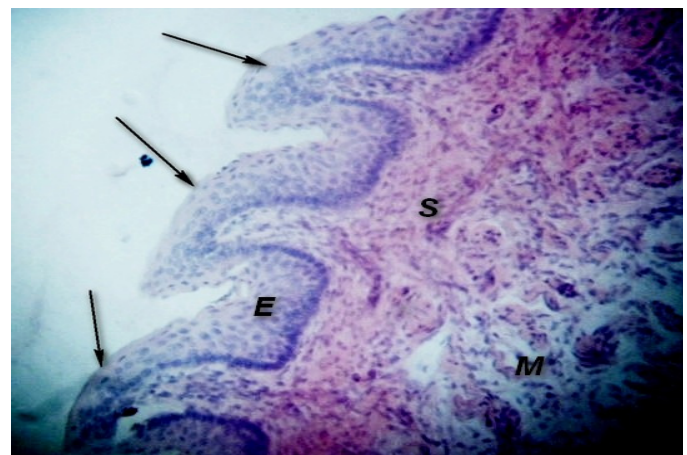


Figure 5: Photomicrograph of camel tongue (LATERAL) at third trimester showing Tunica mucosa (E), Tunica submucosa (S) and Tunica muscularis (M) with developed non-keratinized stratified squamous epithelium (red arrow) lenticular papillae and developed differentiated skeletal muscle (M) H & E x300.

Specialization of the lingual muscles also followed the same trend of development, from immature muscle fibres to mature differentiated muscle. At the first trimester, the three layers were clearly seen with slight differentiation of the epithelia into the formation of the lingual papillae (Figure 3 and 5). At second trimester, there was development of the three layers, with differentiation of the epithelial cells in the forming the papillae, with clear evidence of the differentiation among the papillae and the muscles of the tongue (Figure 3-5).

At third trimester, the three layers were more differentiated with developed epithelial cells into differentiated lingual papillae. The maturity of the tongue can be said to continue after birth, with the formation of non-keratinised stratified squamous epithelium and the

further differentiation of the muscle which were clearly evident in one-year old camel not seen at third trimester (Bello, *et al.* 2013). The above findings is in agreement with the study of Salehi, *et al.* (2010) on morphologic observations of some lingual papillae in *Camelus dromedarius* embryos, who observed that tongues of the foetuses of about 60 days old showed epithelial thickenings of 4-6 layers of epithelial cells on the dorsum and on the apex of the tongue (Figure 3).

Conclusion

Base on the above finding, the result shown that, the development of lingual papillae was found to be in succession i.e from the stages of ordinary epithelial cell linings with undifferentiated protrusions (papillae) to the development into differentiated papillae, then finally to the developed papillae, with continuous maturity at post-natal stage. These were seen with advancement in gestational age from first trimester through second trimester and to third trimester of age. Specialization of the lingual muscles also followed the same trend of development, from immature unorganised muscle fibres to immature organised fibres and finally matured organised differentiated muscle, with continuous maturity at post-natal stage.

References

1. Agungpriyono S., *et al.* "Morphology of the Dorsal Lingual papillae in the Lesser Mouse Deer, *Tragulus javanicus*". *Journal of Anatomy* 187.pt 3 (1995): 635-640.
2. Banks, W. J. (1992). *Applied Veterinary Histology*, Third Edition pp 327 – 331. Mosby Year Book.
3. Bello A., *et al.* "A biometric study of the digestive tract of one-humped camel (*Camelus dromedarius*) fetuses". *Scientific Journal of Zoology* 1.1 (2012): 11-16.
4. Bello A., *et al.* "Histomorphological Studies of the Prenatal Development of Oesophagus of One humped Camel (*Camelus dromedarius*)". *Scientific Journal of Agricultural* 1.4 (2012): 100-104.
5. Chamorro CA., *et al.* "Comparative scanning electron-microscopic study of the lingual papillae in two species of domestic animals (*Equus caballus* and *Bos taurus*). I. Gustatory Papillae". *Acta Anatomica* 1.132 (1988): 83-87.
6. Cho CH., *et al.* "Morphological study on the development of the tongue in fetuses and neonates of Korean native goat (*Capra hircus*)". *Korea Agricultural Science Digital Library* 45.4 (2005): 477-484.
7. Dellman H. *Textbook of Veterinary Histology*. Philadelphia, Lea and Febiger (2006): 477-483.
8. El-Wishy AB., *et al.* "Functional changes in the pregnant camel with special reference to fetal growth". *British Veterinary Journal* 137.5 (1981): 527-537.
9. Emura S., *et al.* "Morphology of the lingual papillae in the roan antelope". *Okajimas Folia Anatomica Japonica* 88.3 (2011): 127-131.
10. Erdogan S., *et al.* "Anatomical and scanning electron microscopic investigations of the tongue and laryngeal entrance in the long-legged buzzard (*Buteo rufinus*)". *Microscopy Research and Technique* 75.9 (2012): 1245-1252.
11. Erdunchaolu E., *et al.* "Characteristics of dorsal lingual papillae of the Bactrian camel (*Camelus bactrianus*)". *Anatomia, Histologia, Embryologia* 30.3 (2001): 147-151.
12. Erdunchaolu K., *et al.* "Morphological characterization of gland cells of glandular sac area in the complex stomach of the Bactrian camel (*Camelus bactrianus*)". *Anatomia, Histologia, Embryologia* 28.3 (1999): 183-191.
13. Franco A., *et al.* "Histomorphometric analysis of the abomasum of sheep during development". *Annals of Anatomy* 53.7 (175): 119-125.
14. Fujimoto S., *et al.* "Pre and post-natal development of rabbit foliate papillae with reference to foliate gutter formation and taste bud differentiation". *Microscopy Research and Technique* 1.26 (1993): 120-132.
15. Iwasaki A. "Evolution of the structure and function of the vertebrate tongue". *Journal of Anatomy* 201.1 (2002): 1-13.
16. Iwasaki S and Kumakura M. "An ultrastructural study of the dorsal lingual epithelium of rat snake (*Elaphe quadrivigata*)". *Annals of Anatomy* 176.5 (1994): 455-462.

17. Iwasaki S., *et al.* "Histological and ultrastructural study of the lingual epithelium of juvenile pacific turtle". *Acta Anatomica* 178.3 (1996): 143-250.
18. Iwasaki S., *et al.* "Study by scanning electron microscopy of the morphogenesis of three papillae in the mouse". *Acta Anatomica* 157.1 (1996): 41-52.
19. Iwasaki S., *et al.* "Study by electron microscopy of three lingual papillae in the rat". *The Anatomical Record* 247.4 (1997): 528-541.
20. Jackowiak H and Godynicki S. "The scanning electron microscopic study of lingual papillae in the silver fox (*Vulpes vulpes fulva*)". *Annals of Anatomy* 186.2 (2004): 179-183.
21. Kumar P., *et al.* "Tongue papillae in goat: A scanning electron-microscopic study". *Anatomia, Histologia, Embryologia* 27.6 (1998): 355-357.
22. Kurtul I and Atalgm HS. "Scanning electron microscopic study on the structure of the lingual papillae of the Saanen goat". *Small Ruminant Research* 80.1 (2008): 52-56.
23. QayyumMA., *et al.* "Scanning Electron Microscopic Study of the Lingual Papillae of the One Humped Camel (*Camelus dromedarius*)". *Journal of Anatomy* 160 (1988): 21-26.
24. Qayyum MA., *et al.* "Histological Observations on the Tongue of One-humped Camel, *Camelus camelus*". *Functional and Developmental Morphology* 1.3 (1991): 23-26.
25. Salehi E., *et al.* "The morphological observations of some lingual papillae in *Camelus dromedarius* embryos". *Journal of Animal and Veterinary Advances* 9.3 (2010): 514-518.
26. Tadjalli M and Pazhoomand R. "Tongue papillae in lambs: A scanning electron microscopic study". *Small Ruminant Research* 54.1-2 (2004): 157-164.
27. Wilson RT. Technical Centre for Agricultural and Rural Cooperation. Macmillan Education Ltd. Hong Kong. (1998): Camels P64-90.
28. Wilson RT. "Studies on the livestock of Southern Darfur. Sudan V. Notes on Camels". *Tropical Animal Health Production* 10.1 (1987): 19-25.